

Real-Time Strain Imaging for Prostate Cancer Diagnostics – Early Detection and Biopsy Guidance

U. Scheipers¹, A. Lorenz², A. Pesavento²,
H. J. Sommerfeld³, M. Garcia-Schürmann³, K. Kühne³,
T. Senge³, S. Philippou⁴, H. Ermert¹

¹ Lehrstuhl für Hochfrequenztechnik, Ruhr-Universität Bochum

² LP-IT Innovative Technologies GmbH, Bochum

³ Urologische Universitätsklinik, Marienhospital Herne

⁴ Institut für Pathologie, Augusta-Krankenanstalt, Bochum

Overview

- Motivation
- Methods
- Principle of Strain Imaging
- Fast Phase Root Seeking
- Clinical Study: Early Detection
- Clinical Study: Biopsy Guidance
- Conclusion

Motivation

Prostate cancer is ...

... one of the highest cancer risks in men
in the western world

... among the highest in cancer mortality statistics

Current methods of diagnostics ...

... lack reliability (DRE, TRUS, PSA)

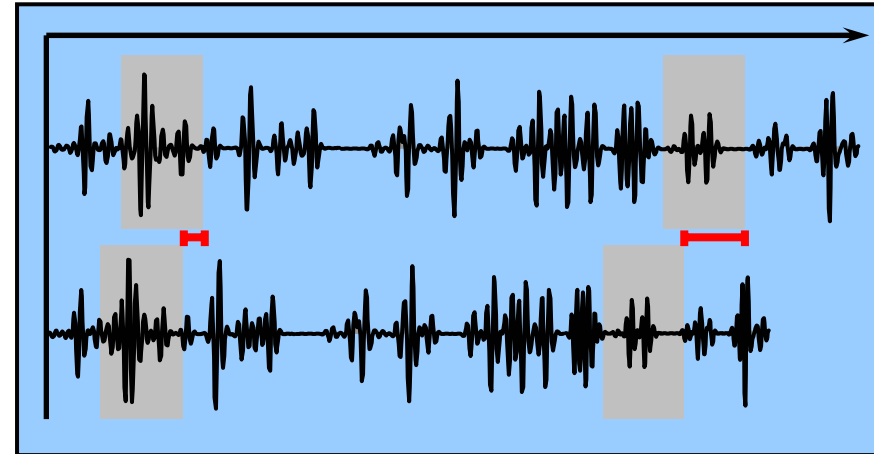
... are operator dependent (DRE, TRUS)

Current therapies ...

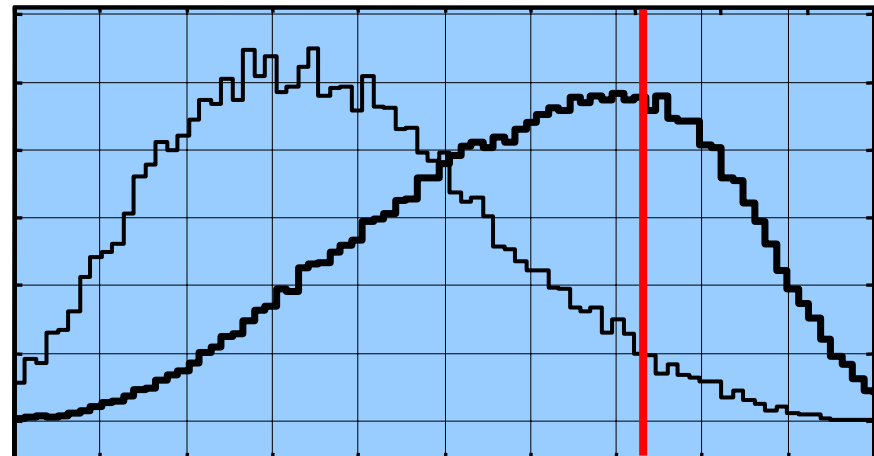
... are only successful at an early stage

New Modalities

Real-Time
Strain Imaging



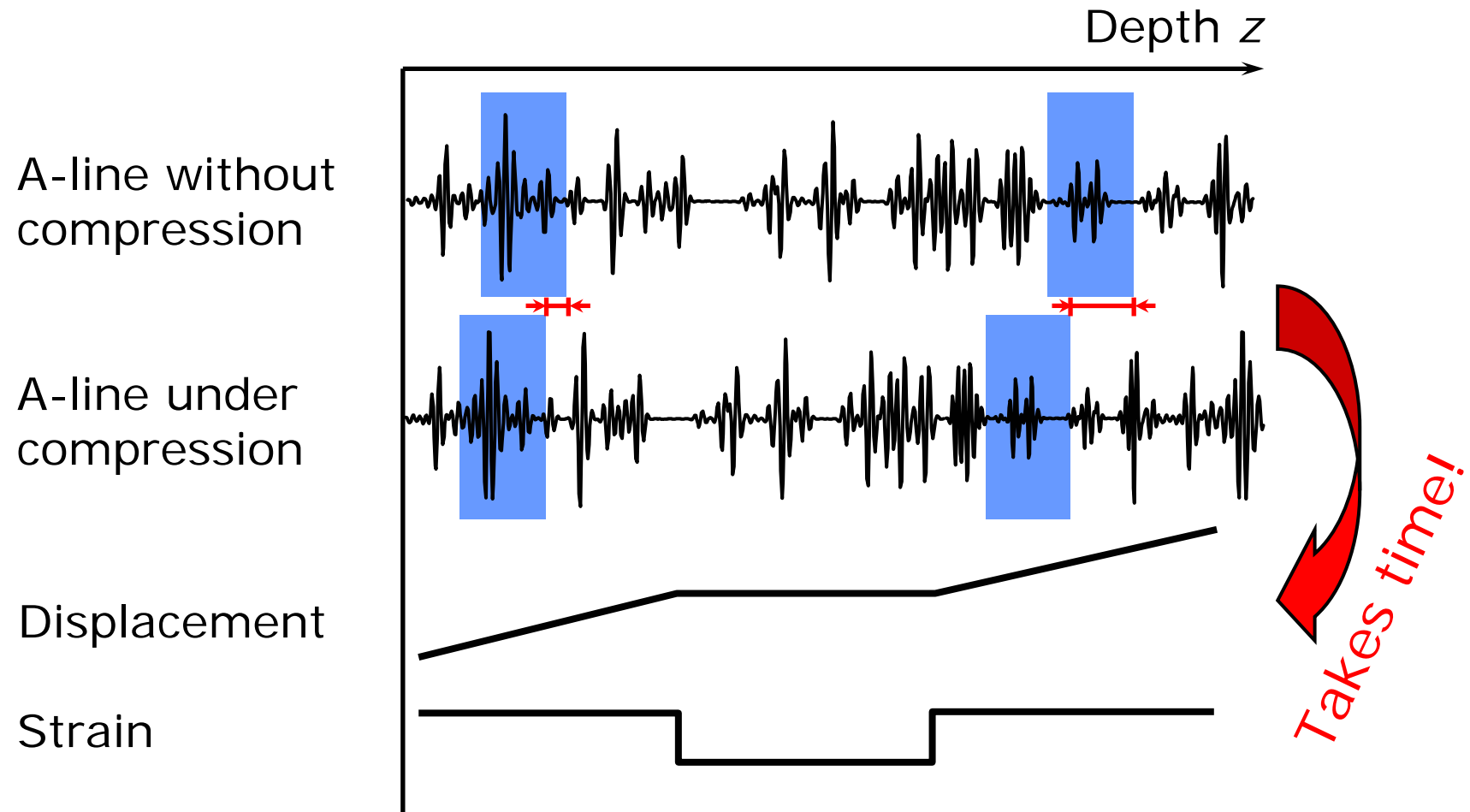
Ultrasonic
Tissue
Characterization



Methods

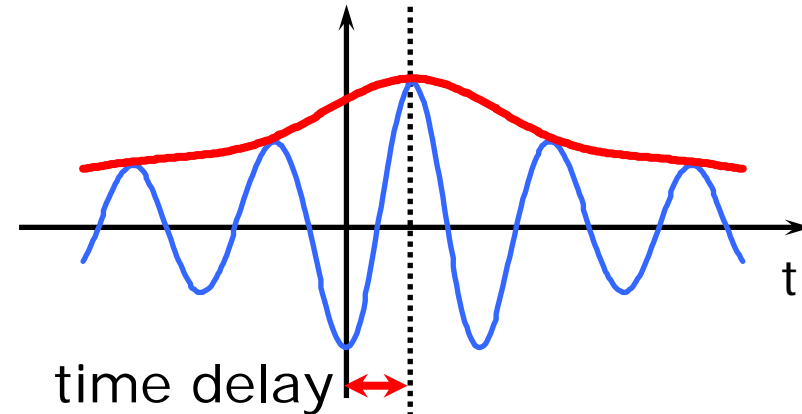
- Not all types of carcinoma are visible with B-mode ultrasound (prostate: 1/3 isoechoic)...
- ...but most tumors are stiffer than normal tissue (see palpation)
- Small tumors at deep positions can hardly be found by digital rectal examination
- Strain Imaging can visualize these types of carcinoma
- Developed at Ruhr-University Bochum:
First Real-Time Strain Imaging system worldwide 1999
Today: calculation of 40+ fps at 100 x 100 points
- Validated results in prostate diagnostics

Principle of Strain Imaging

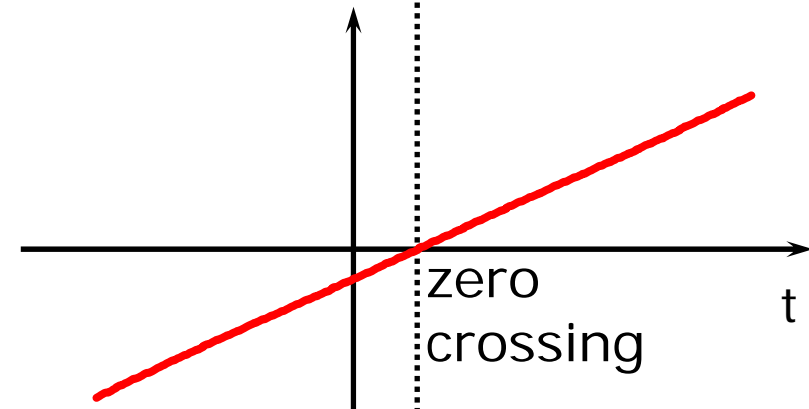


Fast Phase Root Seeking

Analysis of magnitude of cross-correlation function
→ Typical maximum search
→ Involves time consuming interpolations



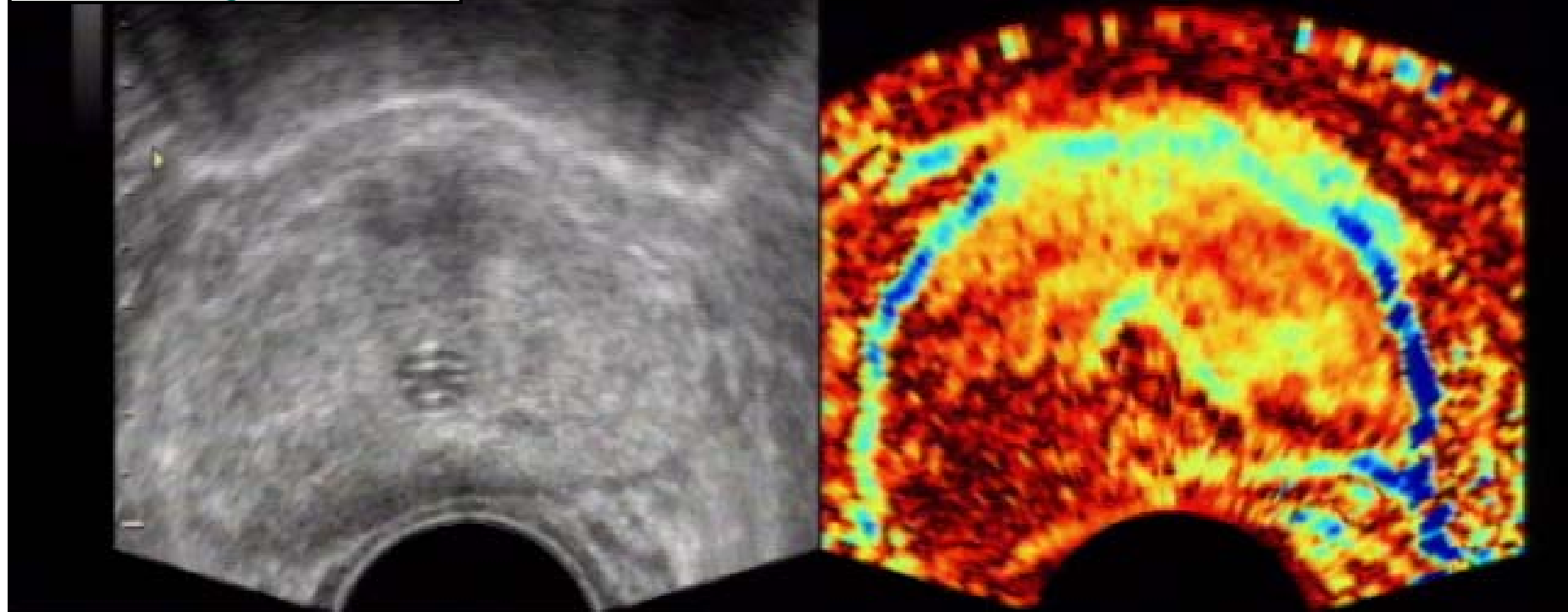
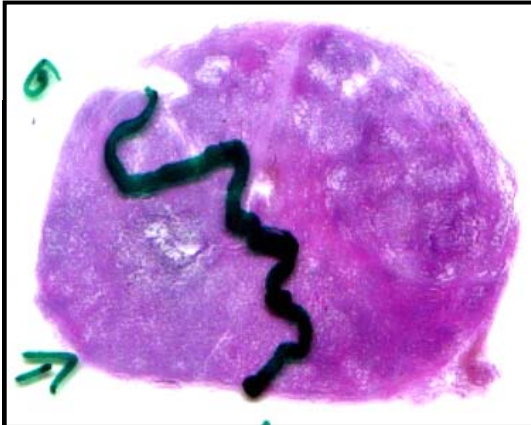
Analysis of phase of cross-correlation function
→ Phase can be considered linear at root
→ Modified Newton algorithm to find root



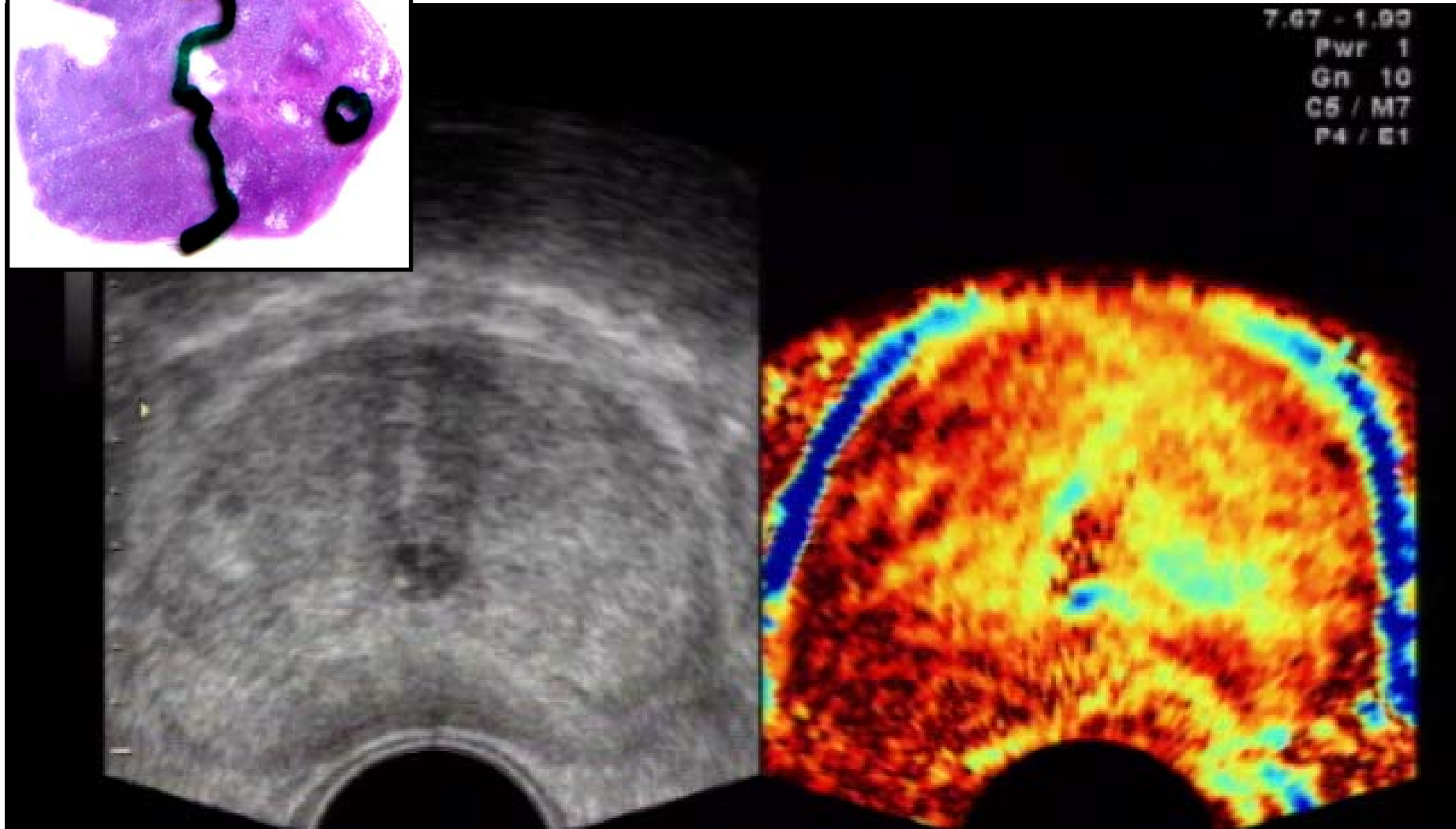
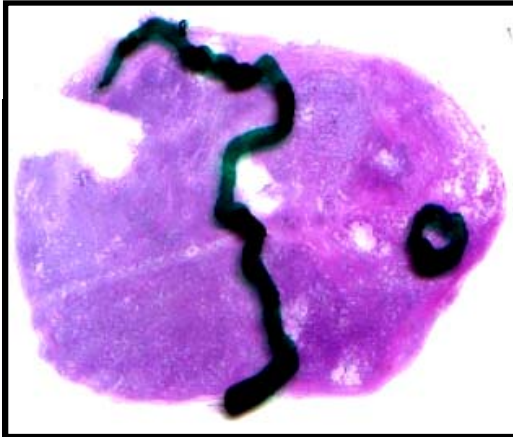Clinical Study: Early Detection

- 260 patients
- All patients suspicious PSA, DRE or TRUS
- Histological findings as gold standard
- B-mode ultrasound imaging:
sensitivity = 34 %
- Real-Time Strain Imaging & B-mode:
sensitivity = 76 %
specificity = 81 %

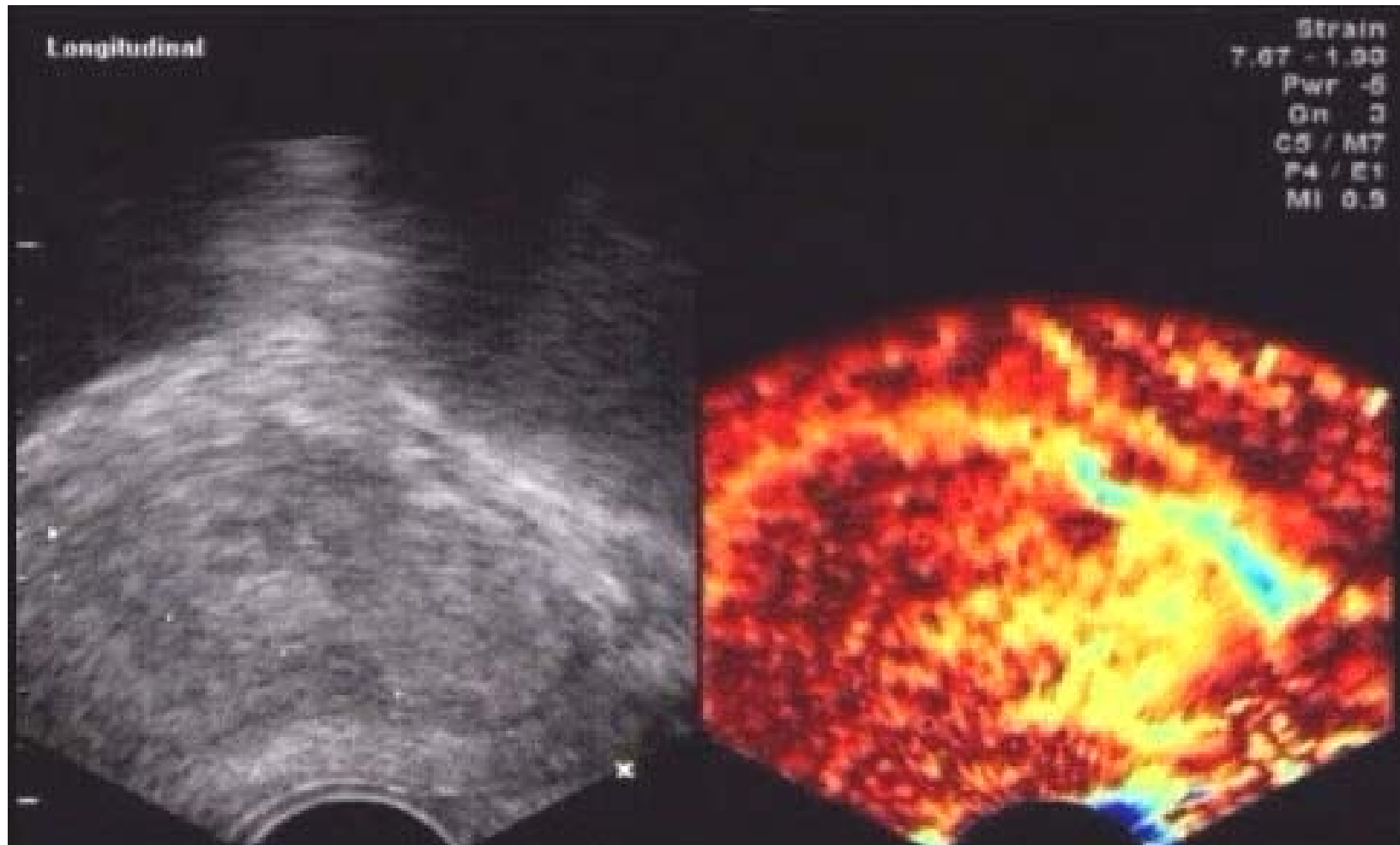
Fully Digital System, 7.5 MHz



Fully Digital System, 7.5 MHz



Biopsy: Longitudinal Mode



Conclusion

- Real-Time Strain Imaging can detect isoechoic tumors
- Improved early detection of prostate carcinoma is possible
- Biopsy guidance and planning can be improved:
 - Reduction of false negative results
 - Reduction of cores possible
- 'Easy to learn' procedure

Thank you!

